

Excessive accumulation of calcium and movement of parathyroid hormone (PTH) in the olfactory system by zinc deficiency

Takao KURIYAMA¹⁾, Kenichi TOMIYAMA¹⁾, Moritoshi NIHIRA¹⁾, Tomomi JYOHO¹⁾, Takayuki TAKEUCHI²⁾,
Yukihiro NAKANO²⁾, Harunobu NAKASHIMA³⁾, Yoshikazu MATSUDA⁴⁾ and Yasuaki ARAKAWA¹⁾

¹⁾*Department of Hygiene & Preventive Medicine, Faculty of Health Sciences, The University of Shizuoka**

²⁾*Research Reactor Institute, Kyoto University***

³⁾*Osaka Prefectural Institute of Public Health****

⁴⁾*Central Research Institute, Japan Clinic Co., Ltd.*****

Summary

Zinc deficiency induced an excessive accumulation of calcium in the olfactory system. This calcium localization was parallel with the degree of symptom manifestation of zinc deficiency. Therefore, to investigate the mechanism on the calcium localization in the olfactory system, the movement of parathyroid hormone (PTH), cAMP and inositol triphosphate (IP₃) which play a part in olfactory signal transduction and Ca-homeostasis were analyzed in the olfactory epithelium, olfactory bulb and cerebrospinal fluid of zinc deficient rats.

Results were as follows; 1) Calcium showed a remarkable decrease in the cerebrospinal fluid and a remarkable increase in the olfactory tissues. 2) Magnesium also showed a decrease in the cerebrospinal fluid and increases in the olfactory tissues, although the movements were much lower than those of calcium. 3) PTH showed significant increases in both the cerebrospinal fluid and the olfactory tissues at the progress period. However, significant decreases in the olfactory tissues and a remarkable increase in the cerebrospinal fluid were seen at the perfection period of zinc-deficiency. 4) cAMP revealed excessive increases in the olfactory epithelium and olfactory bulb at the progress period of zinc deficiency. On the other hand, a little decreases in the olfactory epithelium and olfactory bulb were seen at the perfection period of zinc-deficiency. 5) Regarding IP₃, as well as cAMP, excessive increases in the olfactory epithelium and olfactory bulb were seen at the progress period of zinc deficiency. At the perfection period of zinc-deficiency, however, significant decreases were seen in the olfactory tissues.

Deficiency or excess of trace elements induce various kinds of brain lesion¹⁻⁷⁾. In this study, zinc deficiency-induced olfactory lesions (anosmia) were kinetically analyzed from the viewpoints of the movement of trace elements, an inhibition of signal transduction and toxic cell death (necrosis or apoptosis).

In a series of this study, we found remarkable results that zinc deficiency induced an excessive accumulation of calcium in the olfactory system such as olfactory epithelium and olfactory bulb⁸⁻¹¹⁾. This calcium localization was parallel with the degree of symptom manifestation of zinc deficiency. Therefore, to investigate the mechanism on the calcium localization in the olfactory system, the movement of parathyroid hormone (PTH), cAMP and inositol triphosphate (IP₃) which play a part in olfactory signal transduction and Ca-homeostasis were analyzed in the olfac-

*Address : 52-1, Yada, Suruga-ku, Shizuoka 422-8526, Japan

**Address : Kumotori-cho, Sennan-gun, Osaka 590-0494, Japan

***Address : 1-3-69, Nakamichi, Higashinari-ku, Osaka 537-0025, Japan

****Address : 10-1, Kainichi-cho, Uzumasa, Ukyo-ku, Kyoto 616-8555, Japan

tory epithelium, olfactory bulb and cerebrospinal fluid of zinc deficient rats.

Materials and Methods

The animals used in this study were 3 weeks old, SPF Wistar-derived male rats purchased from Japan SLC Inc. (Hamamatsu, Japan). Rats fed zinc-deficient diet (Zn content: 0.05 mg%, Oriental Yeast Co. Ltd) or zinc-supplement diet (control diet, ZnCO₃ added, Zn content: 5.8 mg%, Oriental Yeast Co. Ltd) for 1 week or 4 weeks.

Olfactory epithelium, olfactory bulb and cerebrospinal fluid were collected from rats fed zinc-deficient diet or zinc-supplement diet for 1 week (zinc deficient progress period) or 4 weeks (zinc deficient perfection period) after the starting of feeding.

Concentration of Ca and Mg in the olfactory epithelium, olfactory bulb and cerebrospinal fluid were analyzed by using a thermal neutron activation analysis method¹²⁾.

PTH in the olfactory epithelium, olfactory bulb and cerebrospinal fluid were assayed with a PTH[¹²⁵I] radio immuno assay¹³⁾.

cAMP in the olfactory epithelium and olfactory bulb were assayed with a cAMP[¹²⁵I] radio immuno assay¹⁴⁾.

IP₃ in the olfactory epithelium and olfactory bulb were assayed with a IP₃[³H] radio receptor assay¹⁵⁾.

Results

Figure 1 shows the relationship of calcium, magnesium and PTH in the olfactory epithelium, olfactory bulb and the cerebrospinal fluid of zinc-deficient rats. Concentration of calcium showed a remarkable decrease in the cerebrospinal fluid and remarkable increases in the olfactory tissues. Regarding magnesium, a decrease in the cerebrospinal fluid and increases in the olfactory tissues were seen as well as calcium, although the movements were much lower than those of calcium. PTH levels showed significant increases in both the cerebrospinal fluid and the olfactory tissues at the progress period. However, significant decreases in the olfactory tissues and a remarkable increase in the cerebrospinal fluid were seen at the completed stage of zinc-deficient manifestation.

Figure 2 shows the movement of cAMP and IP₃ in the olfactory epithelium and the olfactory bulb of zinc-deficient rats. Concentration of cAMP showed excessive increases in the olfactory epithelium and olfactory bulb at the progressive stage of zinc deficiency manifestation. On the other hand, a little decrease in the olfactory epithelium and olfactory bulb were seen at the completed stage of zinc-deficient manifestation. Regarding IP₃, as well as cAMP, excessive increases in the olfactory epithelium and olfactory bulb were seen at the early stage of zinc deficiency manifestation. At the completed stage of zinc-deficient manifestation, however, significant decreases were seen in the olfactory tissues.

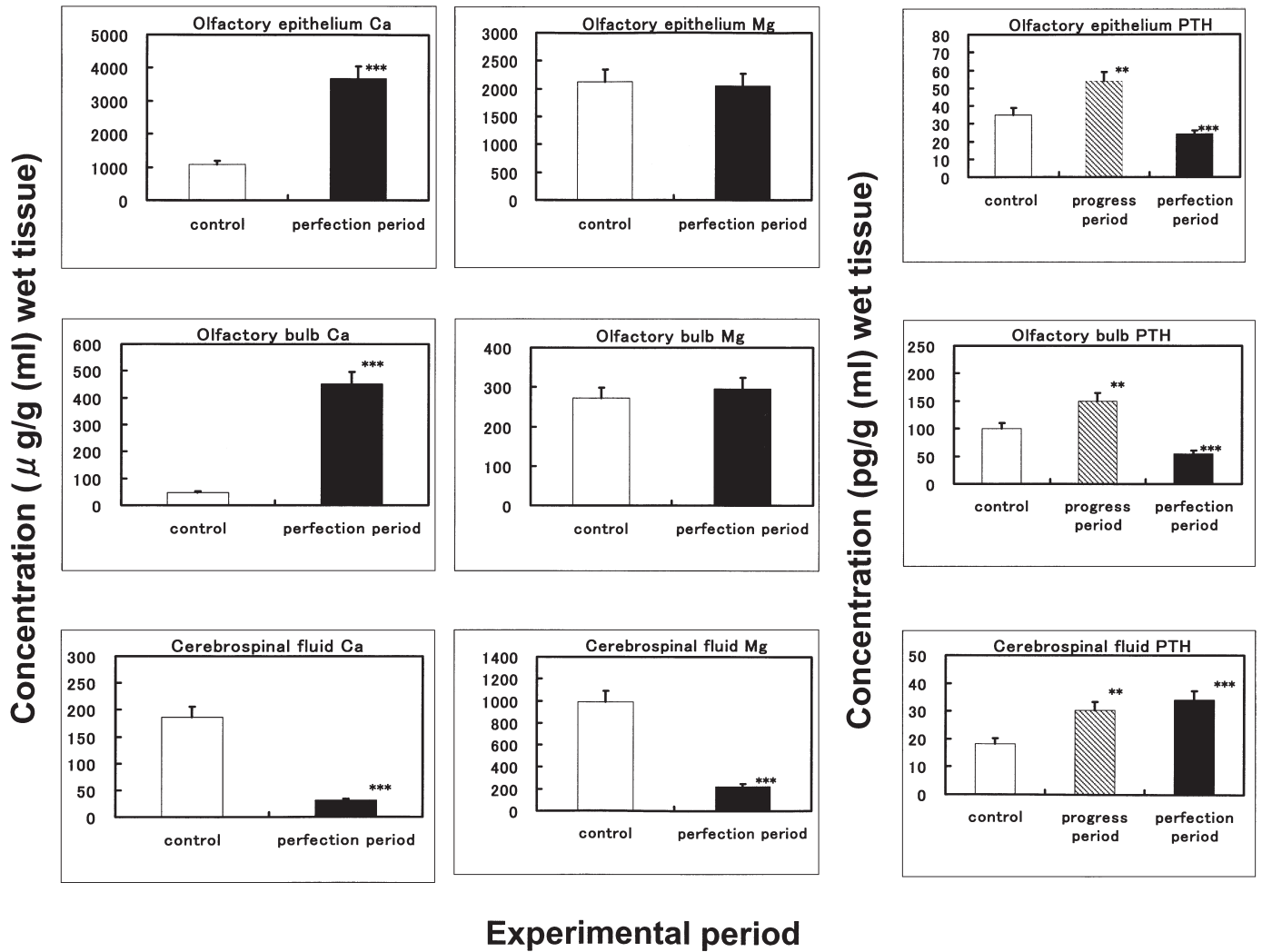
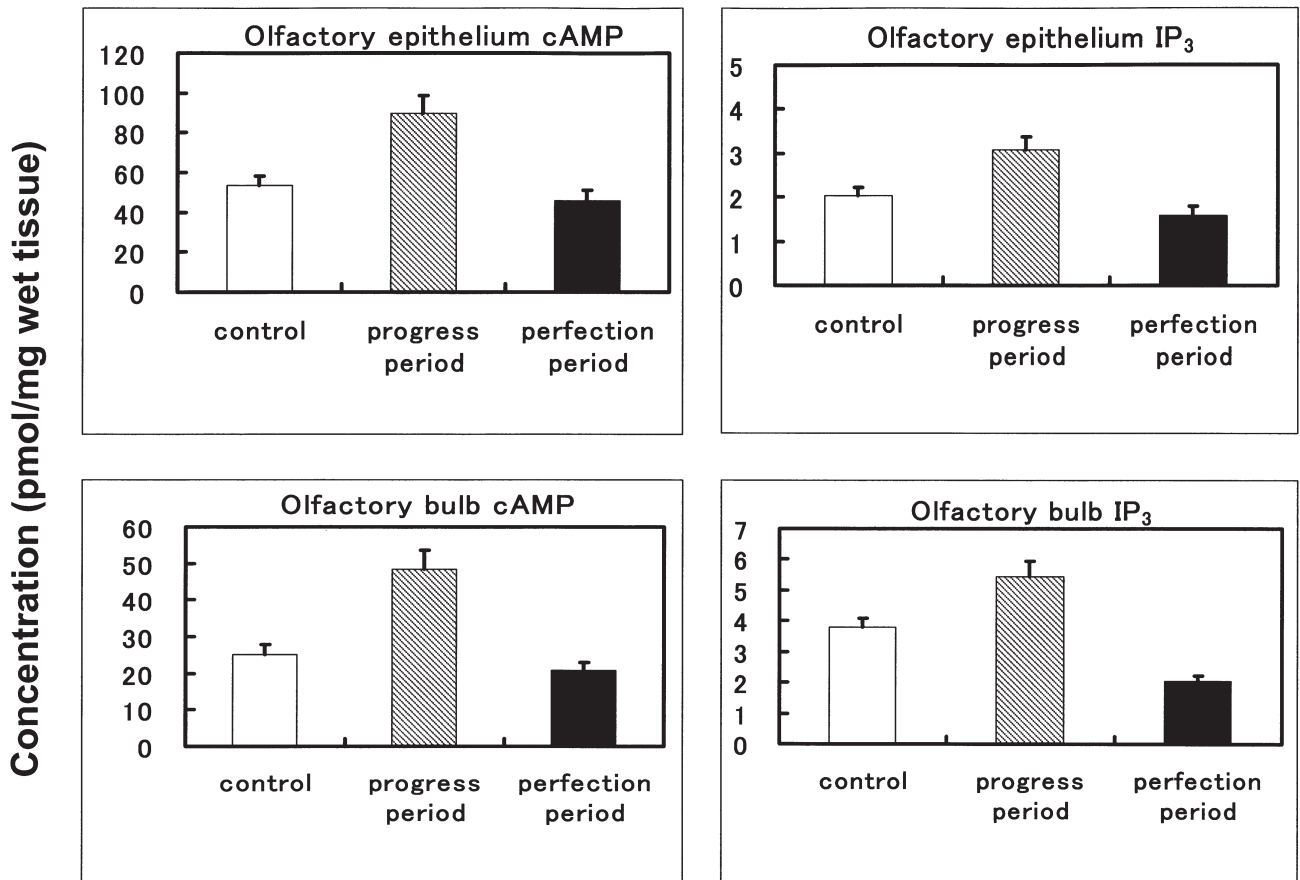


Fig. 1 The relationship of calcium, magnesium and parathyroid hormone(PTH) in the olfactory epithelium, the olfactory bulb and the cerebrospinal fluid of zinc-deficient rats. SPF Wistar-derived male rats (3 week ages) fed with zinc-deficient diet or zinc-supplement diet (control diet) for 1 (progress period) or 4 weeks (perfection period). Vertical bars in the mean of SD; those marked with asterisks differ significantly from the corresponding control value. * $p < 0.05$ ** $p < 0.01$ *** $p < 0.001$



Experimental period

Fig. 2 Movement of cAMP and inositol-1,4,5-triphosphate (IP₃) in the olfactory epithelium and the olfactory bulb of zinc-deficient rats. SPF Wistar-derived male rats (3 week ages) fed with zinc-deficient diet or zinc-supplement diet (control diet) for 1 (progress period) or 4 weeks (perfection period).

Discussion

Concentration of calcium showed a remarkable decrease in the cerebrospinal fluid and a remarkable increase in the olfactory tissues. This means an excessive influx of extracellular Ca²⁺ from the cerebrospinal fluid to the olfactory tissues.

Content of magnesium showed a decrease in the cerebrospinal fluid, but a little increase in the olfactory tissues. This result revealed that influx of extracellular Mg²⁺ from the cerebrospinal fluid to the olfactory tissues was extremely small.

An increase and a decrease of calcium and magnesium are known as hypercalcemia and hypermagnesemia, which were regulated by PTH. Hypercalcemia and hypermagnesemia were recognized in the organs other than the brain. No reports showed PTH production in the brain except for a report referring to PTH production in the brain of sheep¹⁶). We speculated that the excessive accumulation of calcium in the olfactory tissues may be related to PTH in the brain. Our experimental results showed that a significant increases of PTH were seen in both the cerebrospinal fluid and the olfactory tissues, followed by the activation of adenylcyclase by the excessive increases of PTH in the special regions of the brain, excessive increases in the formation of cAMP by the activation of adenylcyclase in the

early stage (progressive stage) of symptom manifestation of zinc deficiency. These results mean an excessive acceleration of extracellular Ca^{2+} -influx to the tissues. At the completed stage of zinc-deficient manifestation, however, significant decreases of PTH in the olfactory tissues and a remarkable increase of PTH in the cerebrospinal fluid were seen. These significant decreases of PTH in the olfactory tissues appear to be due to the decreases in the affinity and bonding amount of PTH to the receptor which are caused by the break-down of metabolic systems and cell death under the long-term abnormal condition. Conversely, a remarkable increase of PTH in the cerebrospinal fluid appear to be due to an excessive acceleration of PTH generation to recovery the low levels of calcium and magnesium in the cerebrospinal fluid and significant decreases of PTH in the olfactory tissues.

cAMP increased in the olfactory epithelium and olfactory bulb at the progressive stage of zinc deficiency manifestation. This means an excessive acceleration of cAMP driving processes such as the activation of adenylcyclase by the excessive increases of PTH at Ca channel. On the other hand, a little decreases of cAMP in the olfactory epithelium and olfactory bulb were seen at the completed stage of zinc-deficient manifestation. These decreases in the tissues appear to be due to the working of negative feed-back, the break-down of metabolic systems and cell death under the long-term abnormal condition. We observed extensive destruction of the cortical neurons at the completed stage of zinc-deficient manifestation (data are not shown).

Regarding IP_3 , as well as cAMP, excessive increases of IP_3 in the olfactory epithelium and olfactory bulb were seen at the early stage of zinc deficiency manifestation. This means an excessive acceleration of IP_3 working processes such as IP_3 -dependent Ca^{2+} channel and intracellular Ca^{2+} -mobilization. At the completed stage of zinc-deficient manifestation, however, remarkable decreases of IP_3 were seen in the olfactory tissues. These remarkable decreases in the tissues appear to be due to the working of negative feed-back, the break-down of metabolic systems and cell death under the long-term abnormal condition, as described above.

Putting all results together, the calcium localization in the olfactory system seems to be due to the processes such as the activation of adenylcyclase by an excessive increase of PTH in the special regions of the brain, excessive increase in the formation of cAMP by the activation of adenylcyclase, disorder of cAMP-activated channels by the excessive increase of cAMP, and an excessive influx of extracellular Ca^{2+} by the disorder of the channels. Moreover, this rapid and excessive increase in the concentration of intracellular Ca^{2+} seems to inhibit CaM-kinase II functions and to activate endonuclease, followed by leading to toxic cell death (necrosis or apoptosis).

References

- 1) Arakawa Y, Igura K, Yoshinari S, Hirano Y, Nakashima H, Ohmori S, Takeuchi T, Nakano Y, Wada O (1996) An excessive accumulation of olfactory calcium and inhibition of olfactory signal transduction by organotin compounds. *Biomed Res Trace Elements* 7: 121 - 122.
- 2) Arakawa Y, Harada C, Murata J, Hirano Y, Igura K, Nakashima H, Ohmori S, Takeuchi T, Nakano Y (1996) The relationship between iron and aluminum of the hippocampus and olfactory bulb in zinc deficiency. *Trace Nutrients Research* 13: 23 - 26.
- 3) Arakawa Y, Igura K, Yoshinari S, Hirano Y, Nakashima H, Ohmori S, Takeuchi T, Nakano Y, Wada O (1996) An excessive accumulation of olfactory calcium and inhibition of olfactory signal transduction by organotin compounds. *Trace Nutrients Research* 13: 63 - 67.
- 4) Arakawa Y, Takeuchi T, Nakano Y, Matsuda Y, Yamaguchi M, Takaya H, Shibata Y, Nakasa T, Okinaka Y, Abe K, Miyazawa T (1999) Organotin-induced olfactory, lesions and its suppression. *Trace Nutrients Research* 16: 41 - 47.

- 5) Arakawa Y, Takeuchi T, Nakano Y, Matsuda Y, Yamaguchi M, Takaya H, Shibata Y, Nakasa T, Okinaka Y, Abe K, Miyazawa T (1999) Organotin-induced olfactory, lesions and its suppression by vitamin E. *Biomed. Res Trace Elements* 10: 217 - 218.
- 6) Hetzel BS (2000) Iodine and neuropsychological development. *J Nutr* 130: 493S - 495S.
- 7) Grantham-McGregor S, Ani C (2001) A review of studies on the effect of iron deficiency on cognitive development in children. *J Nutr* 131: 649S - 666S.
- 8) Arakawa Y, Hirano Y, Murata J, Nakashima H, Takeuchi T, Nakano Y (1995) The relationship between the movement of trace elements and parathyroid hormone(PTH) in the zinc deficiency- and organotin-induced brain lesion. *Trace Nutrients Research* 12: 107 - 112.
- 9) Arakawa Y (1997) Olfactory disorders and calcium localization. *Trace Nutrients Research* 14: 19 - 28.
- 10) Arakawa Y, Takeuchi T, Nakano Y (1998) Morbid aging and trace elements in the brain-olfactory disorders and calcium localization by deficiency and excess of trace elements. *KURRI Progress Report* 1997: 159.
- 11) Arakawa Y, Suzuki H, Takeuchi T, Nakano Y (2000) Morbid aging and trace elements in the brain-olfactory disorders and calcium localization by deficiency and excess of trace elements. *KURRI Progress Report* 1999: 181.
- 12) Arakawa Y, Endo T, Nakashima H, Takeuchi T, Nakano Y (2003) Changes in trace element balances in the breath of hypertension. *Trace Nutrients Research* 20: 89 - 95.
- 13) Hirano Y, Sakazaki H, Arakawa Y, Nakashima H, Takeuchi T, Nakano Y, Wada O (1995) Movement of aluminum and parathyroid hormone (PTH) in the hippocampus by zinc deficiency. *Jpn J Hyg* 50: 349.
- 14) Hirano Y, Yoshinari S, Igura K, Murata J, Harada C, Ohshita Y, Arakawa Y, Nakashima H, Ohmori S, Takeuchi T, Nakano Y, Wada O (1996) Analysis of the mechanism for the olfactory lesion and the excessive accumulation of olfactory calcium by organotins -Movement of inositol-1,4,5-triphosphate(IP₃) participating in an increase in intracellular Ca²⁺ concentration-. *Jpn J Hyg* 51: 333.
- 15) Igura K, Yoshinari S, Hirano Y, Murata J, Harada C, Ohshita Y, Arakawa Y, Nakashima H, Ohmori S, Takeuchi T, Nakano Y, Wada O (1996) Analysis of the mechanism for the olfactory lesion and the excessive accumulation of olfactory calcium by organotins -cAMP -induced extracellular Ca²⁺ influx and changes in activity of Ca²⁺ calmodulin dependent kinase II-. *Jpn J Hyg* 51: 332.
- 16) Balabanova S, Peter J, Reinhardt G (1986) Parathyroid hormone secretion by brain and pituitary of sheep. *Klin Wochenschr* 64: 173 - 176.